Brain stem vascular syndromes

By: Mohammad Edrees Mohammad, MD

- ILOs:

- Knowing the blood supply of brain stem structures.
- Identifying different syndromes resulted from different vascular occulsions.

Blood supply

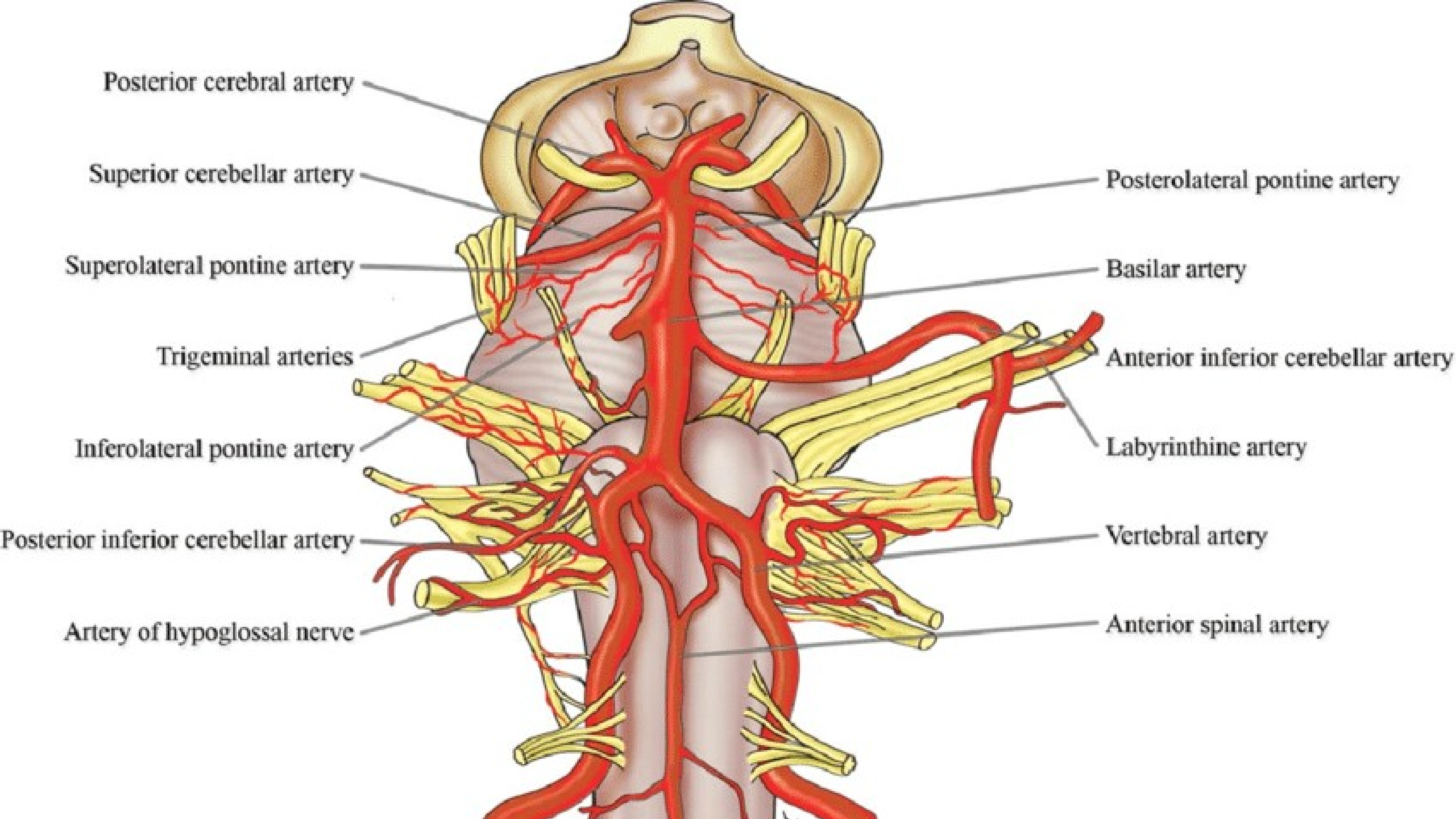
Posterior cerebral artery
Superior cerebellar artery
Superolateral pontine artery
Trigeminal arteries
Inferolateral pontine artery
Posterior inferior cerebellar artery
Artery of hypoglossal nerve
Posterolateral pontine artery
Basilar artery
Anterior inferior cerebellar artery
Labyrinthine artery
Vertebral artery
Anterior spinal artery

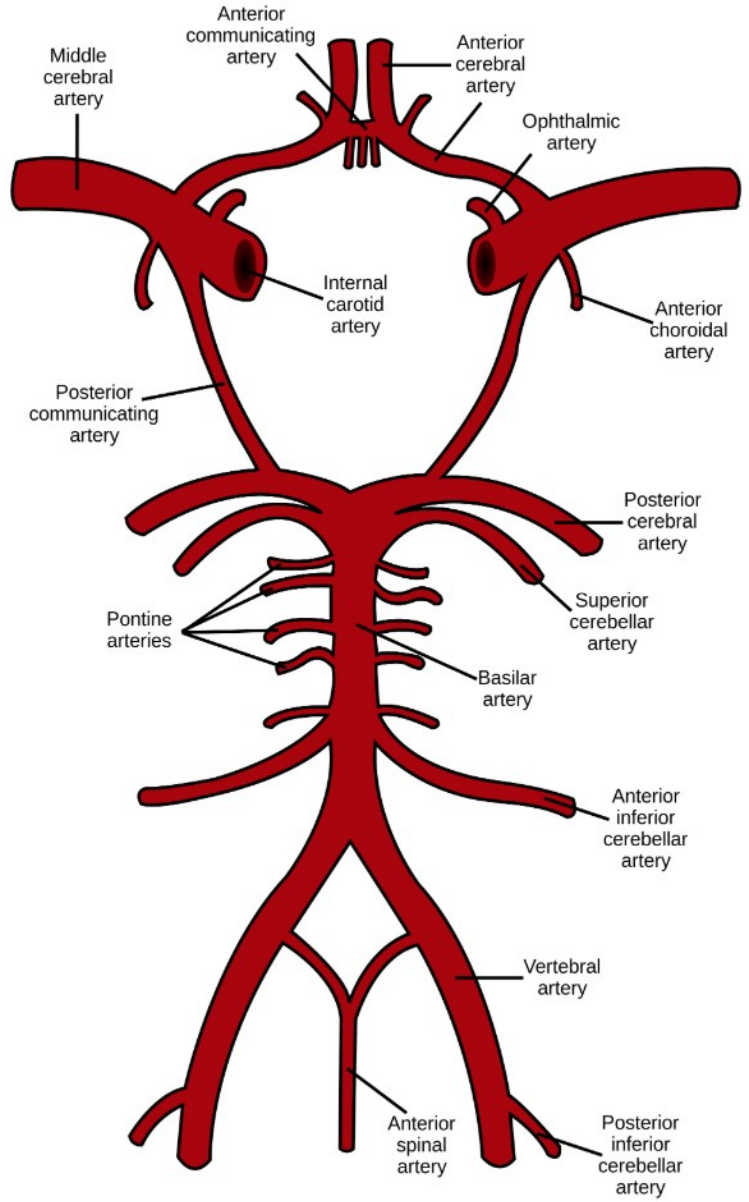
Anterior communicating artery
Middle cerebral artery
Anterior cerebral artery
Ophthalmic artery
Internal carotid artery
Anterior choroidal artery
Posterior communicating artery
Posterior cerebral artery
Superior cerebellar artery
Pontine arteries
Basilar artery
Anterior inferior cerebellar artery
Vertebral artery
Anterior spinal artery
Posterior inferior cerebellar artery

Clinical picture

Syndrome	Signs/Symptoms	Localization	Vascular Supply
Weber	Ipsilesional cranial nerve III palsy, contralesional hemiparesis (including the lower face)	Medial midbrain/cerebral peduncle	Deep penetrating artery from posterior cerebral artery (refer to **Table 2-3**)
Benedikt	Ipsilesional cranial nerve III palsy, contralateral involuntary movements (intention tremor, hemichorea, or hemiathetosis)	Ventral midbrain involving red nucleus	Deep penetrating artery from posterior cerebral artery or paramedian penetrating branches of basilar artery
Nothnagel	Ipsilesional cranial nerve III palsy, contralesional dysmetria, and contralesional limb ataxia	Superior cerebellar peduncle	Deep penetrating artery from posterior cerebral artery
Foville	Ipsilateral cranial nerves VI and VII (lateral gaze palsy, upper and lower facial weakness), with or without contralateral hemiparesis	Caudal pontine tegmentum involving the facial colliculus	Pontine perforator branches off the basilar artery
One-and-a-half	Ipsilateral cranial nerve VI (lateral gaze) palsy, bilateral internuclear ophthalmoplegia	Paramedian pons involving the paramedian pontine reticular formation and medial longitudinal fasciculi	Paramedian pontine perforators off the basilar artery
Wallenberg	Ipsilesional facial and contralesional body hypalgesia and thermoanesthesia; ipsilesional palatal weakness; dysphagia, dysarthria, nystagmus, vertigo, nausea/vomiting; ipsilesional oculosympathetic defect (Horner syndrome); skew deviation, singultus	Lateral medulla	Posterior inferior cerebellar artery (should raise concern for disease in parent vertebral artery)
Dejerine	Ipsilesional tongue weakness and contralesional hemiparesis with or without contralesional loss of proprioception and vibratory sense	Medial medulla	Vertebral artery or anterior spinal artery

[a] Data from Eckerle BJ, Southerland AM, Wiley-Blackwell.[24]

Midbrain vascular syndromes

Medial midbrain syndrome (paramedian branches of upper basilar and proximal posterior cerebral arteries)

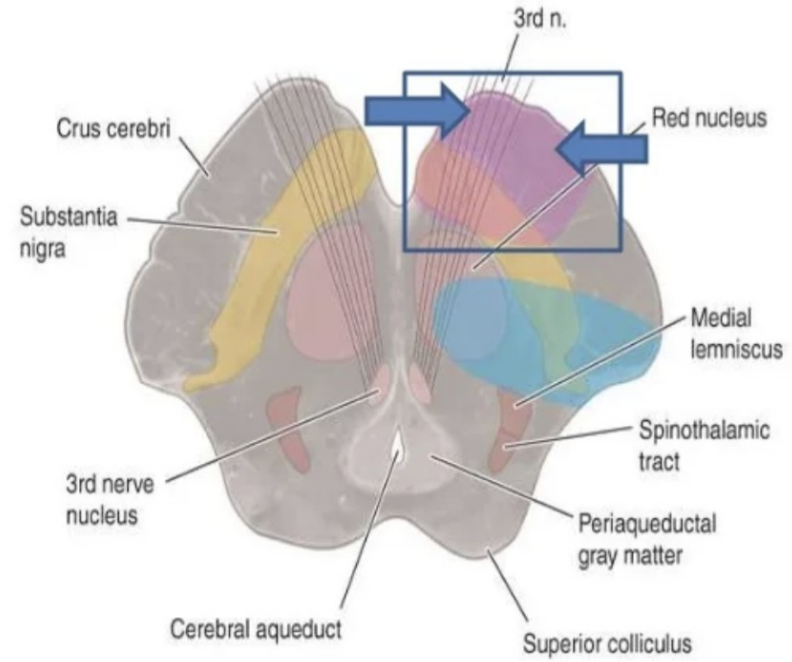

Midbrain syndrome:

Lateral Medial

- ON SIDE OF LESION

  Eye "down and out" secondary to unopposed action of fourth and sixth cranial nerves, with dilated and unresponsive pupil: *Third nerve fibers*

ON OPPOSITE SIDE

- Paralysis of face, arm, and leg: *Corticobulbar and corticospinal tract descending in crus cerebri*

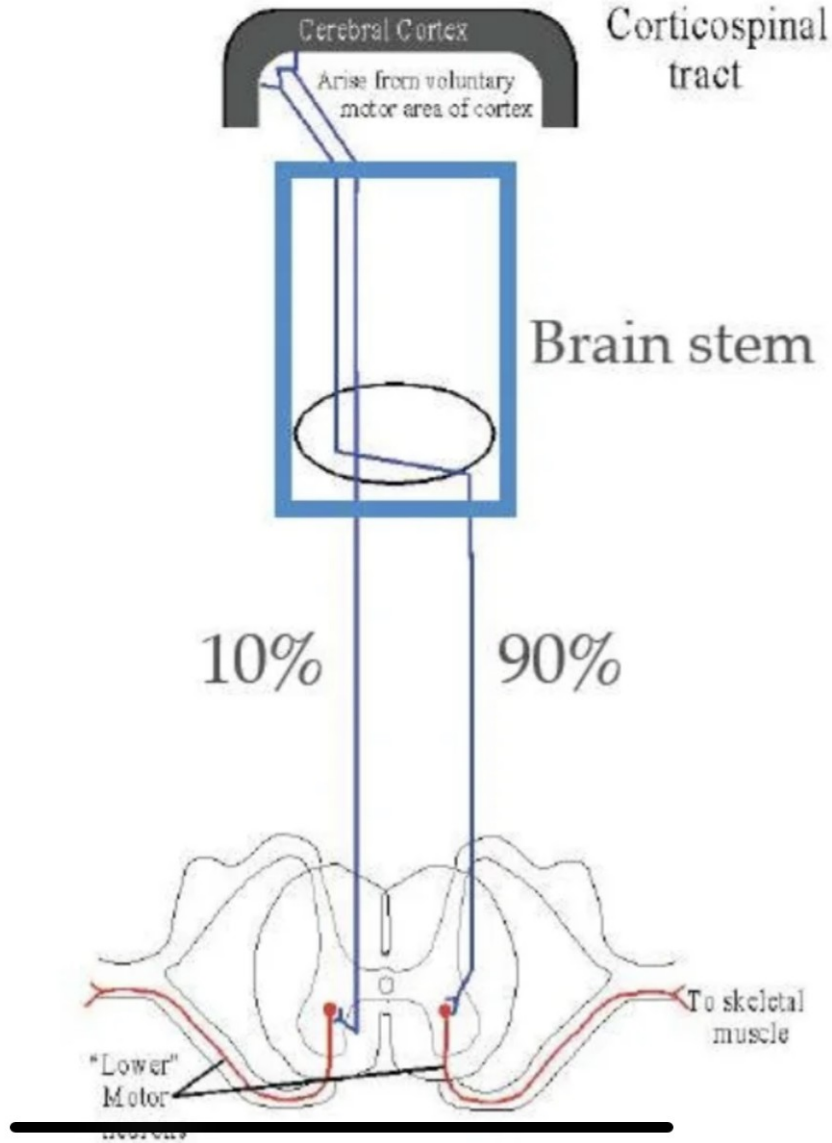
Cerebral Cortex
Arise from voluntary motor area of cortex
Corticospinal tract
Brain stem
10%
90%
To skeletal muscle
"Lower" Motor

Lateral midbrain syndrome (syndrome of small penetrating arteries arising from posterior cerebral artery)

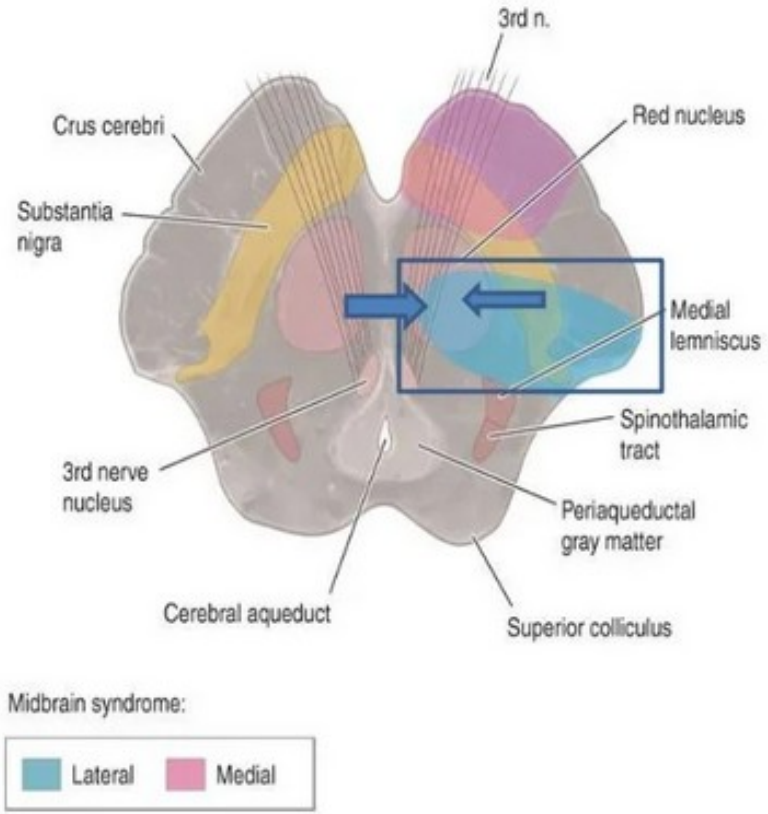

<u>On side of lesion</u>

- Eye "down and out" secondary to unopposed action of fourth and sixth cranial nerves, with dilated and unresponsive pupil: *Third nerve fibers and/or third nerve nucleus*

<u>On side opposite lesion</u>

- Hemiataxia, hyperkinesias, tremor: *Red nucleus, dentatorubrothalamic pathway*

Mid brain syndromes

Eponym[b]	Site	Cranial Nerves Involved	Tracts Involved	Signs
Weber syndrome	Base of midbrain	III	Corticospinal tract	Oculomotor palsy with crossed hemiplegia
Claude syndrome	Tegmentum of midbrain	III	Red nucleus and brachium conjunctivum	Oculomotor palsy with contralateral cerebellar ataxia and tremor
Benedikt syndrome	Tegmentum of midbrain	III	Red nucleus, corticospinal tract, and brachium conjunctivum	Oculomotor palsy with contralateral cerebellar ataxia, tremor, and corticospinal signs
Nothnagel syndrome	Tectum of midbrain	Unilateral or bilateral III	Superior cerebellar peduncles	Ocular palsies, paralysis of gaze, and cerebellar ataxia
Parinaud syndrome	Dorsal midbrain		Supranuclear mechanism for upward gaze and other structures in periaqueductal gray matter	Paralysis of upward gaze and accommodation; fixed pupils

Pontine syndromes

Medial inferior pontine syndrome

(occlusion of paramedian branch of basilar artery)

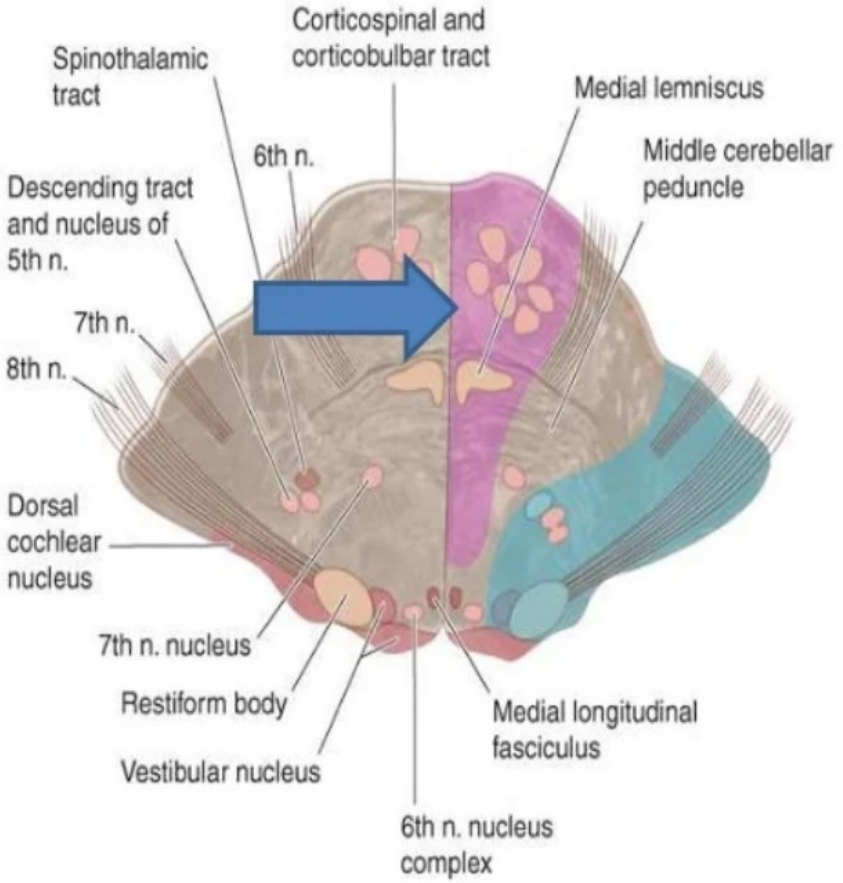

Inferior pontine syndrome:

<u>On side of lesion</u>

- Paralysis of conjugate gaze to side of lesion (preservation of convergence): *Center for conjugate lateral gaze(PPRF)*
- Nystagmus: *Vestibular nucleus*
- Ataxia of limbs and gait: Likely *middle cerebellar peduncle*
- Diplopia on lateral gaze: *Abducens nerve*

<u>On side opposite lesion</u>

- Paralysis of face, arm, and leg: *Corticobulbar and corticospinal tract in lower pons*
- Impaired tactile and proprioceptive sense over one-half of the body: *Medial lemniscus*

Lateral inferior pontine syndrome

(occlusion of anterior inferior cerebellar artery)

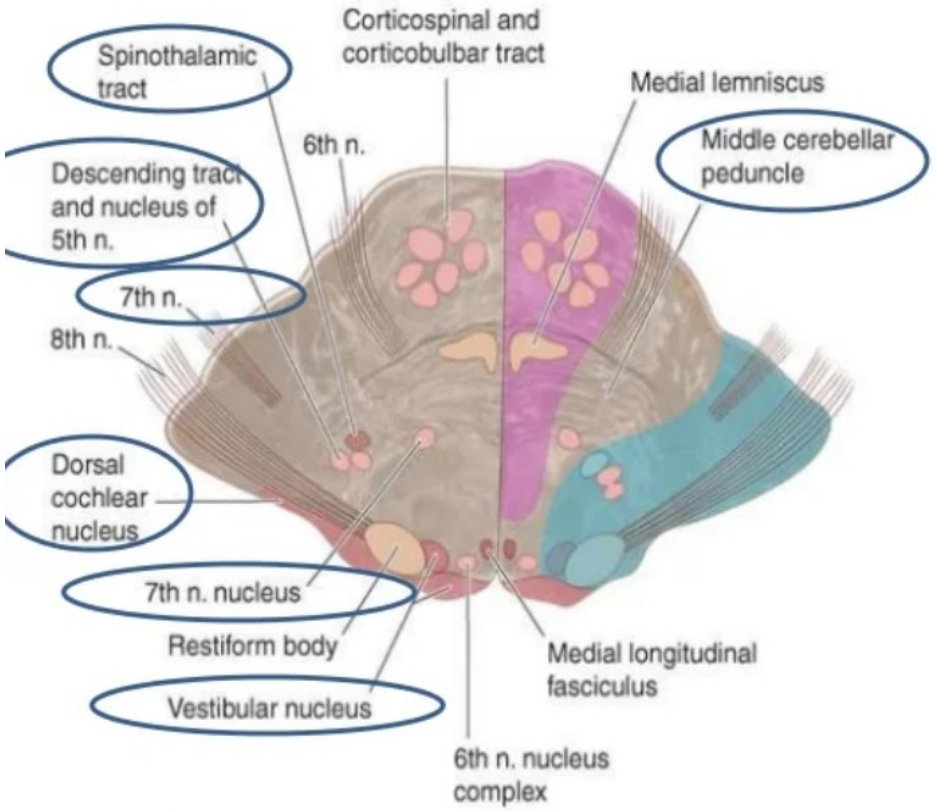

Inferior pontine syndrome:

<u>On side of lesion</u>

Horizontal and vertical nystagmus, vertigo, nausea, vomiting, oscillopsia: *Vestibular nerve or nucleus*

Facial paralysis: *Seventh nerve*

Paralysis of conjugate gaze to side of lesion: *Center for conjugate lateral gaze*

Deafness, tinnitus: *Auditory nerve or cochlear nucleus*

Ataxia: *Middle cerebellar peduncle and cerebellar hemisphere*

Impaired sensation over face: *Descending tract and nucleus fifth nerve*

<u>On side opposite lesion</u>

Impaired pain and thermal sense over one-half the body (may include face): *Spinothalamic tract*

Medial midpontine syndrome

(paramedian branch of midbasilar artery)

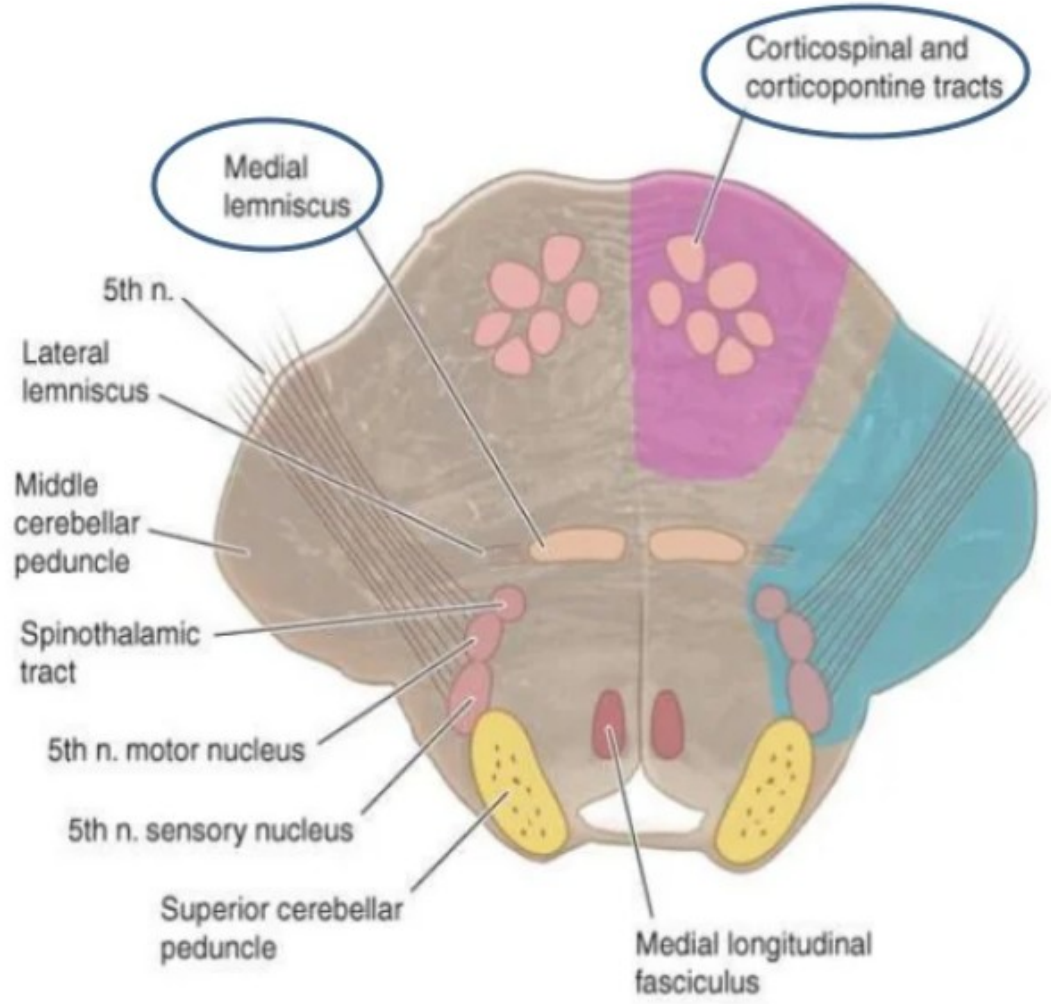

<u>On side of lesion</u>

Ataxia of limbs and gait (more prominent in bilateral involvement): *Pontine nuclei*

<u>On side opposite lesion</u>

Paralysis of face, arm, and leg: *Corticobulbar and corticospinal tract*

Variable impaired touch and proprioception when lesion extends posteriorly: *Medial lemniscus*

Lateral midpontine syndrome

(short circumferential artery)

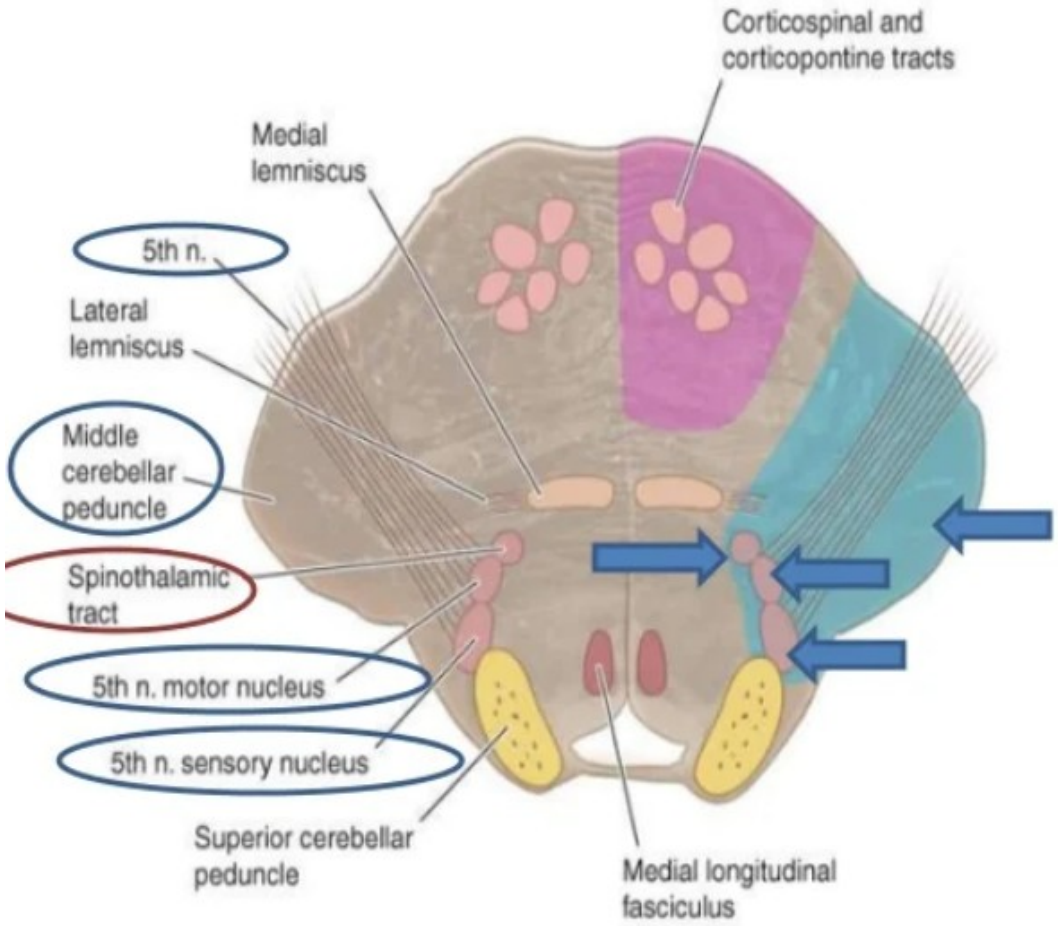

On side of lesion

- Ataxia of limbs: *Middle cerebellar peduncle*
- Paralysis of muscles of mastication: *Motor fibers or nucleus of fifth nerve*
- Impaired sensation over side of face: *Sensory fibers or nucleus of fifth nerve*

On side opposite lesion

- Impaired pain and thermal sense on limbs and trunk: *Spinothalamic tract*

Medial superior pontine syndrome

(paramedian branches of upper basilar artery)

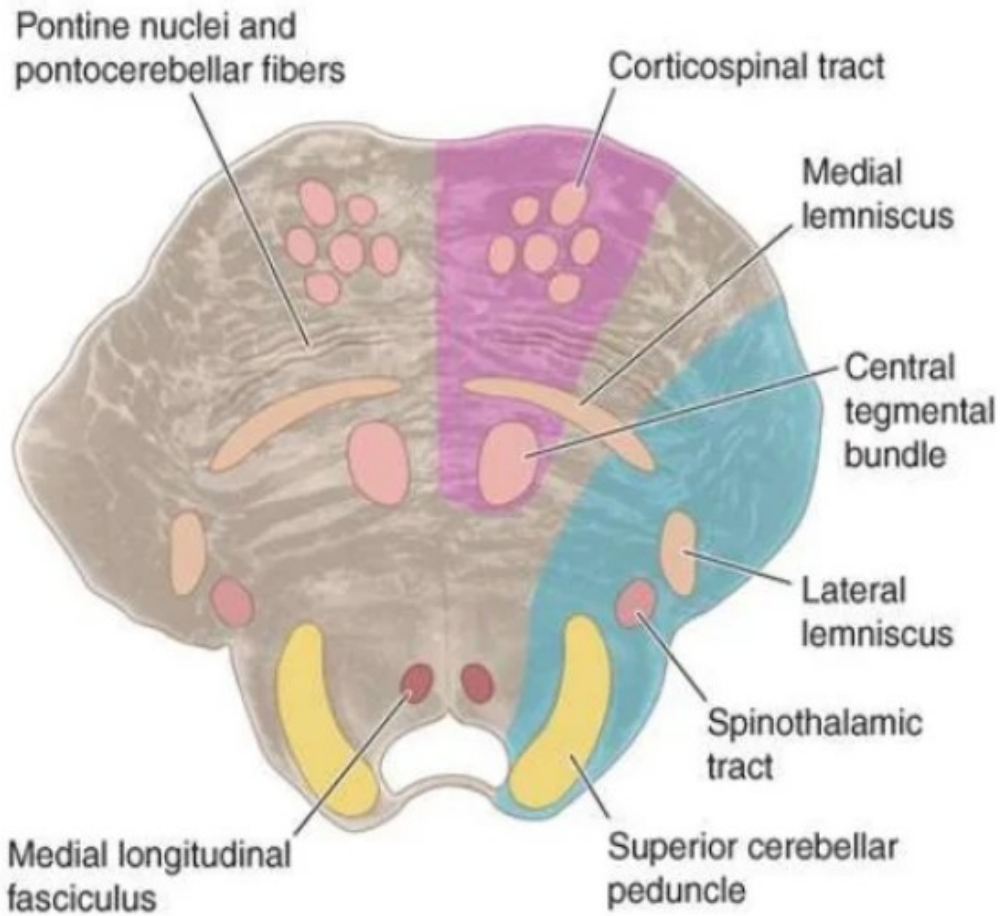

<u>On side of lesion</u>

- Cerebellar ataxia (probably): *Superior and/or middle cerebellar peduncle*
- Internuclear ophthalmoplegia: *Medial longitudinal fasciculus*
- Myoclonic syndrome, of palate, pharynx, vocal cords, respiratory apparatus, face, oculomotor apparatus, etc.: — *central tegmental bundle.*

<u>On side opposite lesion</u>

- Paralysis of face, arm, and leg: *Corticobulbar and corticospinal tract*
- Rarely touch, vibration, and position are affected(arm>leg): *Medial lemniscus*

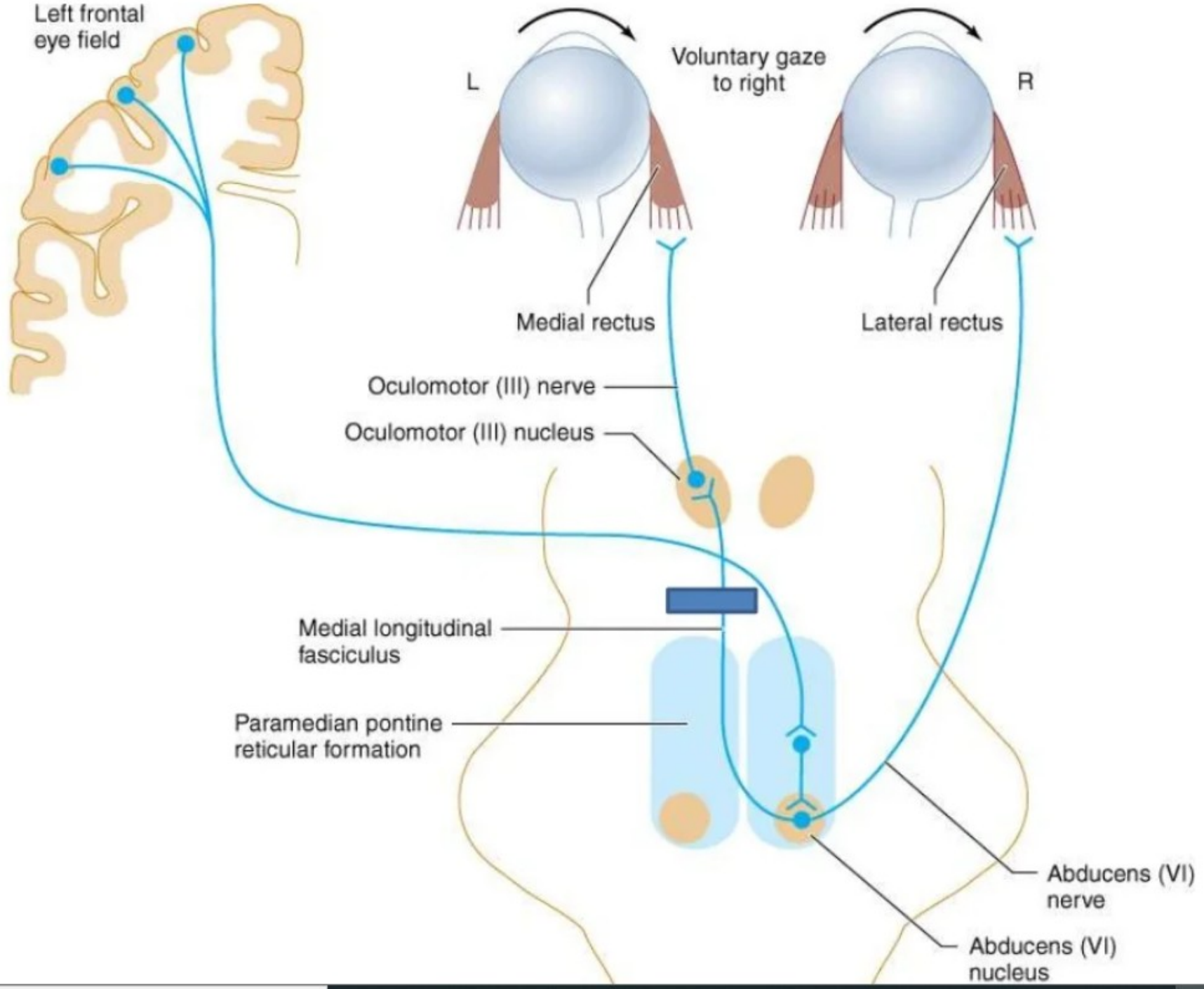
Left frontal eye field
L
Voluntary gaze to right
R
Medial rectus
Lateral rectus
Oculomotor (III) nerve
Oculomotor (III) nucleus
Medial longitudinal fasciculus
Paramedian pontine reticular formation
Abducens (VI) nerve
Abducens (VI) nucleus

Rt internuclear ophthalmoplegia

One and a half syndrome

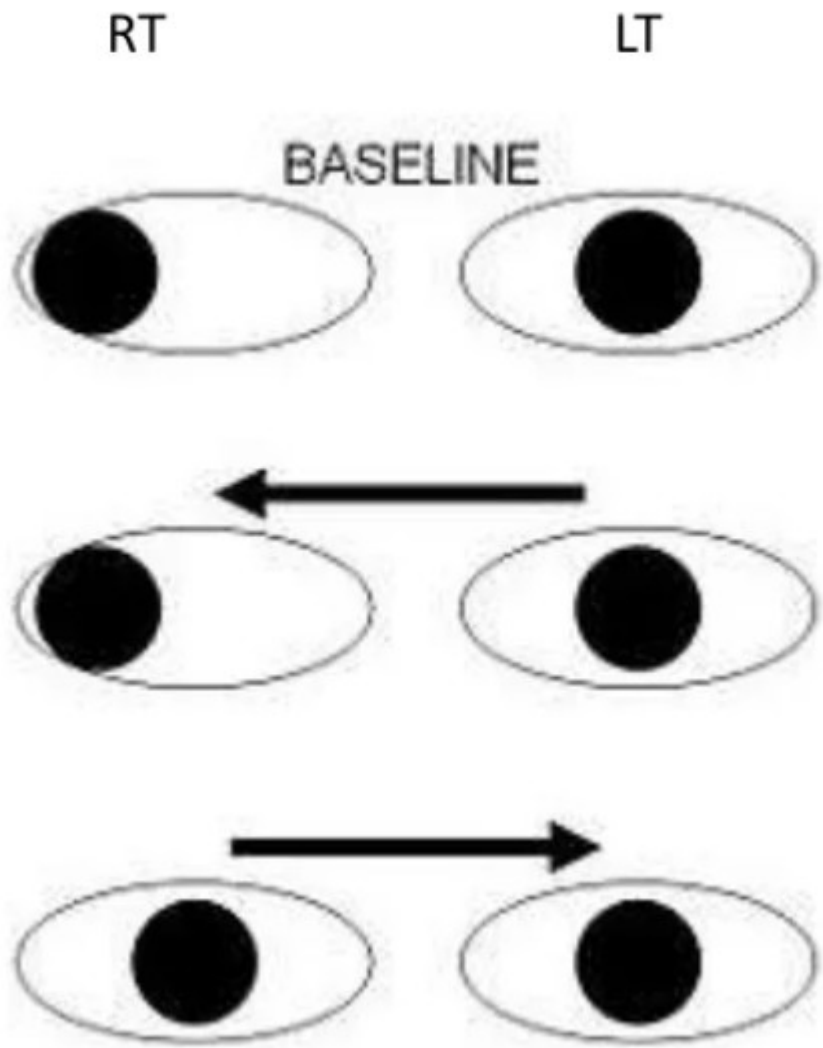

Lateral superior pontine syndrome

(syndrome of superior cerebellar artery)

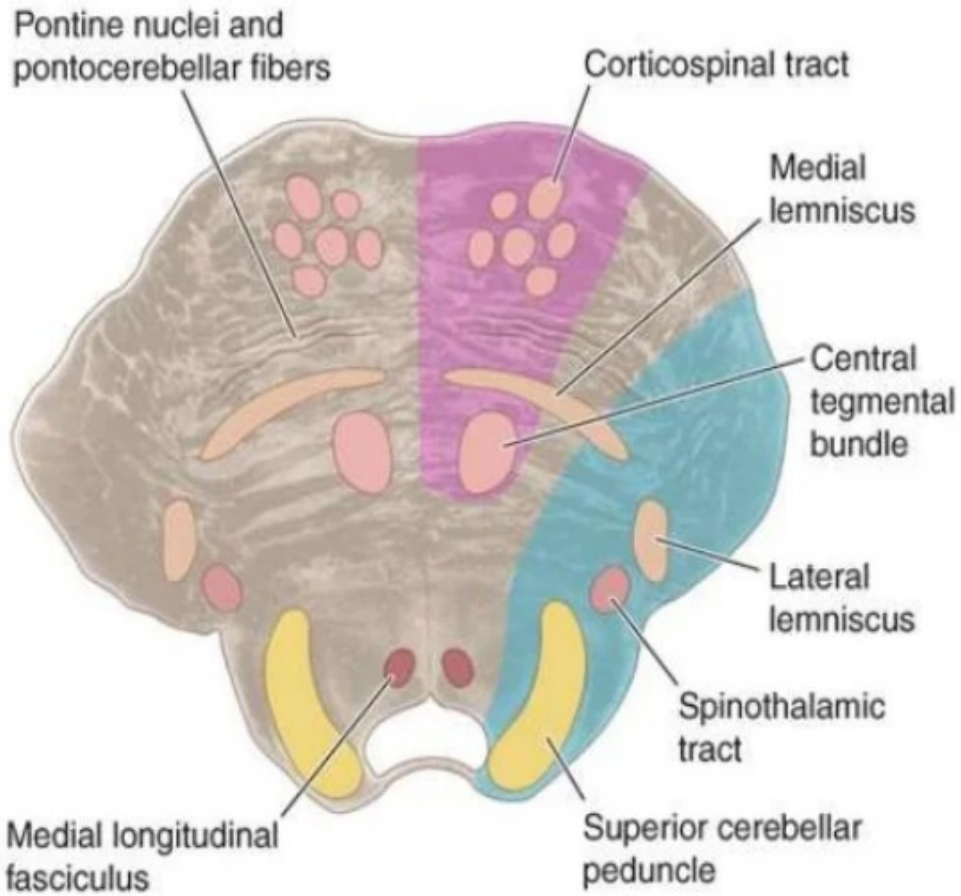

<u>On side of lesion</u>

- Ataxia of limbs and gait, falling to side of lesion: *Middle and superior cerebellar peduncles, superior surface of cerebellum, dentate nucleus*
- Dizziness, nausea, vomiting; horizontal nystagmus: *Vestibular nucleus*
- Paresis of conjugate gaze (ipsilateral): *Pontine contralateral gaze*
- Miosis, ptosis, decreased sweating over face (Horner's syndrome): *Descending sympathetic fibers*

<u>On side opposite lesion</u>

- Impaired pain and thermal sense on face, limbs, and trunk: *Spinothalamic tract*
- Impaired touch, vibration, and position sense, more in leg than arm : *Medial lemniscus (lateral portion)*

Medulla

Medial medullary syndrome

(occlusion of vertebral artery or of branch of vertebral or lower basilar artery)

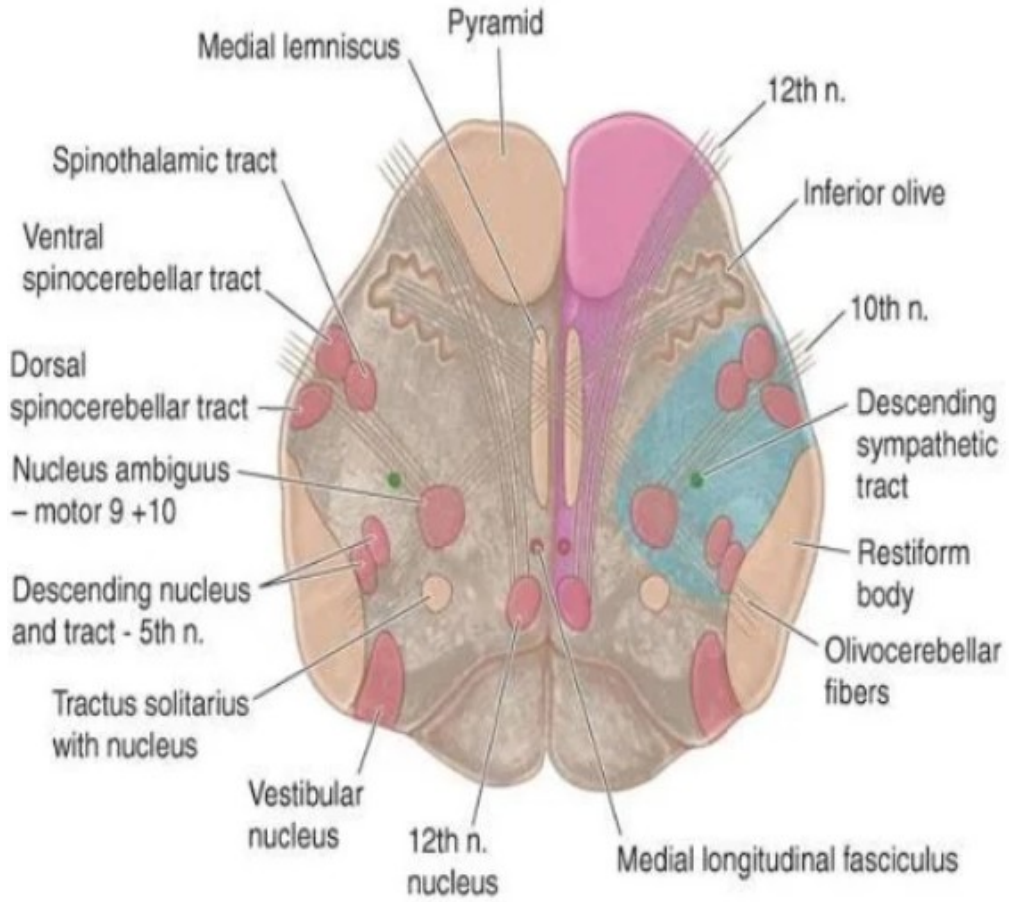

On side of lesion

- Paralysis with atrophy of one-half half the tongue: *Ipsilateral twelfth nerve*

On side opposite lesion

- Paralysis of arm and leg, sparing face; impaired tactile and proprioceptive sense over one-half the body: *Contralateral pyramidal tract and medial lemniscus*

Lateral medullary syndrome

(occlusion of any of five vessels may be responsible—vertebral, posterior inferior cerebellar, superior, middle, or inferior lateral medullary arteries)

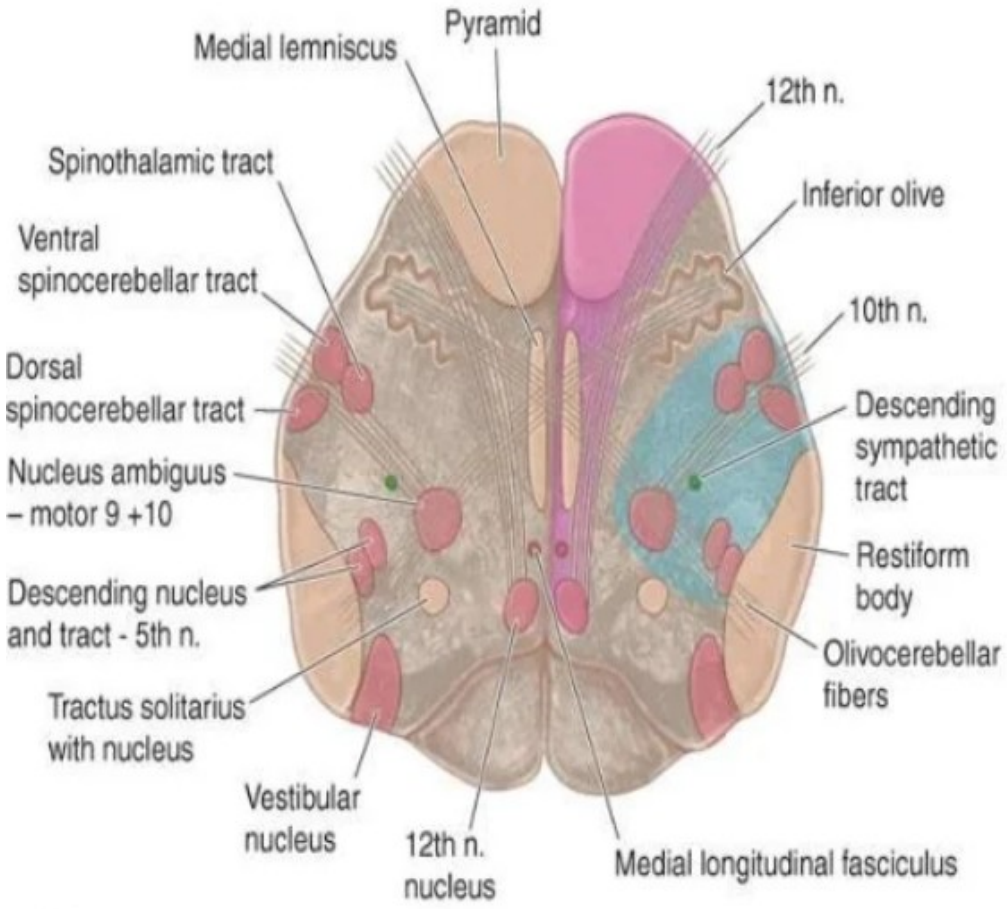

Medullary syndrome:

Lateral Medial

<u>On side of lesion</u>

- Pain, numbness, impaired sensation over one-half the face: *Descending tract and nucleus fifth nerve*
- Ataxia of limbs, falling to side of lesion: *Uncertain—restiform body, cerebellar hemisphere, cerebellar fibers, spinocerebellar tract (?)*
- Nystagmus, diplopia, oscillopsia, vertigo, nausea, vomiting: *Vestibular nucleus*
- Horner's syndrome (miosis, ptosis, decreased sweating): *Descending sympathetic tract*
- Dysphagia, hoarseness, paralysis of palate, paralysis of vocal cord, diminished gag reflex: *Issuing fibers ninth and tenth nerves*
- Loss of taste: *Nucleus and tractus solitarius*
- Numbness of ipsilateral arm, trunk, or leg: *Cuneate and gracile nuclei*
- Weakness of lower face: *Genuflected upper motor neuron fibers to ipsilateral facial nucleus*

<u>On side opposite lesion</u>

- Impaired pain and thermal sense over half the body, sometimes face: *Spinothalamic tract*

Quiz

- A 65-year-old man has a history of hypertension.
- He presents with sudden onset dysarthria, vomiting hiccup and vertigo.
- On examination, he has:
  - ✔ Right sided Horner's syndrome,
  - ✔ Right-sided cerebellar ataxia,
  - ✔ Loss of pain and temperature sensation on the right side of the face,
  - ✔ Loss of pain and temperature sensation in the left upper and lower limbs.

- **Which one of the following is the likely diagnosis?**

A. Cerebellar infarct

B. Inferior parietal infarct

C. Superior temporal infarct

D. Subthalamic nucleus infarct

E. Lateral medullary infarct

- In the lateral medullary syndrome “PICA occlusion” (inferior cerebellar artery involvement), there are:
  - ✔ 9th and 10th nerve involvement leads to dysphagia and dysarthria.
  - ✔ Ipsilateral Horner's syndrome.
  - ✔ Ipsilateral facial sensory loss, and contralateral pain/temperature sensory loss to upper and lower